

Improvement of Walking Ability Using Hybrid Assistive Limb Training in a Patient with Severe Thoracic Myelopathy caused by Ossification of the Posterior Longitudinal Ligament - A Case Report

Shigeki Kubota^{1,2}, Tetsuya Abe², Kengo Fujii², Aiki Marushima³, Tomoyuki Ueno⁴, Ayumu Haginoya⁴, Ayumu Endo⁴, Hideki Kadone⁵, Hiroaki Kawamoto⁶, Yukiyo Shimizu⁴, Yasushi Hada⁴, Akira Matsumura³, Yoshiyuki Sankai⁶ and Masashi Yamazaki^{2,5}

¹Division of Regenerative Medicine for Musculoskeletal System, Faculty of Medicine, University of Tsukuba, Ibaraki, Japan

²Department of Orthopaedic Surgery, Faculty of Medicine, University of Tsukuba, Ibaraki, Japan

³Department of Neurosurgery, Faculty of Medicine, University of Tsukuba, Ibaraki, Japan

⁴Department of Rehabilitation Medicine, University of Tsukuba Hospital, Ibaraki, Japan

⁵Center for Innovating Medicine and Engineering (CIME), University of Tsukuba Hospital, Ibaraki, Japan

⁶Faculty of Systems and Information Engineering, University of Tsukuba, Ibaraki, Japan

Abstract

The purpose of this study was to report the improvement of walking ability using Hybrid Assistive Limb (HAL) training in a case of severe thoracic myelopathy caused by ossification of the posterior longitudinal ligament (OPLL). The patient received HAL training 2-3 times per week (10 sessions) beginning on the thirteenth postoperative day. The patient's walking ability and lower muscles strength were significantly improved. It suggests that HAL training in the early postoperative phase has the potential to be an effective rehabilitation tool to improve functional ambulation in surgically-treated thoracic OPLL patients with inability of walk.

Keywords: Hybrid assistive limb; Ossification of the posterior longitudinal ligament; Rehabilitation

Introduction

It is estimated that 7,400 people (range 6,000 – 8,900) in Japan have ossification of the posterior longitudinal ligament (OPLL), prevalence of 6.33 per 100,000 people [1]. Because OPLL causes spinal canal stenosis leading to mechanical compression of the spinal cord and nerve roots, clinical symptoms such as motor paralysis of the upper and lower-extremity, pain, sensory disturbance, and urinary disturbance are prevalent in cervical OPLL. Surgical treatment is chosen when there are deficits in finger dexterity, gait disturbance, urinary disturbance, or in cases in which conservative treatment is refractory.

The exoskeleton robot hybrid assistive limb (HAL) (Figure 1) can support the wearer's motion by adjusting the level and timing of the assistive torque provided to each joint according to the surface muscle action potential on the anterior and posterior surface of the wearer's thigh, as well as by using pressure sensors in the shoes [2]. The HAL can appear as an actual motion, and it can enhance the wearer's motion through their muscle action potential. The HAL training, using muscle activity, has the potential to intensify the feedback by inducing an appropriate motion more strongly than other standard robot training

[3-6]. Thus, after HAL training, patients with limited mobility can improve their walking abilities. The feasibility of rehabilitation using HAL training has been shown for multiple disorders [7], including training in eight patients with chronic spinal cord injuries [8]. However, for rehabilitation in case of severe thoracic myelopathy caused by OPLL, it is difficult to secure enough training quantity because of the burden on medical therapists. Even if a patient's condition were too severe for medical therapists to provide adequate rehabilitation training, HAL might still make adequate training possible. We report here the improvement of walking ability using the HAL training in a case of severe thoracic myelopathy caused by OPLL.

Case Report

Patient

A 43-year-old man had numbness on the anterior the right femoral region four months prior that prevented him from walking. His paraplegia had progressed rapidly, and he was diagnosed with thoracic OPLL. He scored 3-4 on MMT (Manual muscle testing) for both lower limbs, and had sensory disturbance below the region of the umbilicus. In addition, he had urinary disturbance and the sphincter dysfunction. The CT (computed tomography) myelography and MRI (Magnetic resonance imaging) showed the spinal cord compression extending from T8-T11, and from L1 to L3 (Figure 2). Thoracic level 10/11 was the most affected region, with approximately 80% of the spinal canal occupied by OPLL.

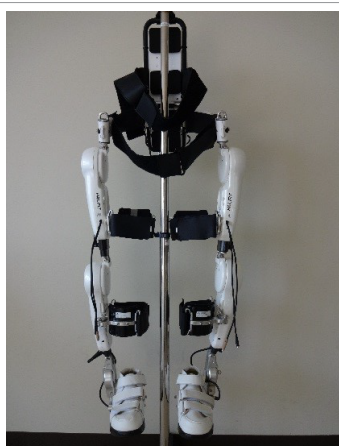

Figure 1: The robot suit HAL®.

***Corresponding author:** Masashi Yamazaki M.D, PhD, Department of Orthopaedic Surgery, Faculty of Medicine, University of Tsukuba, 1-1-1, Tennodai, Tsukuba, Ibaraki, 305-8575, Japan. Tel: +81-29-853-3219; Fax: +81-29-853-3162; E-mail: masashiy@md.tsukuba.ac.jp

Received February 15, 2016; **Accepted** February 25, 2016; **Published** February 27, 2016

Citation: Kubota S, Abe T, Fujii K, Marushima A, Ueno T, et al. (2016) Improvement of Walking Ability Using Hybrid Assistive Limb Training in a Patient with Severe Thoracic Myelopathy caused by Ossification of the Posterior Longitudinal Ligament - A Case Report. J Spine S7: 003.doi:10.4172/2165-7939.S7-003

Copyright: © 2016 Kubota S, et al. This is an open-access article distributed under the terms of the Creative Commons Attribution License, which permits unrestricted use, distribution, and reproduction in any medium, provided the original author and source are credited.

Posterior decompression with instrument fusion using rods surgery was performed from T7 to L3 (Figure 3). The patient was able to sit on the bed by the third postoperative day. Conventional physical training such as sitting exercise on the bed, standing exercise, and gait training with a walking device was started on the third postoperative day, and he was able to move in a wheelchair by the fourth at postoperative day. He started gait training with a walker one week after surgery. After that, he was able to ambulate with a pick up walker under supervision.

HAL Training

He received additional HAL training 2-3 times per week (10 sessions) starting two weeks after surgery (Figure 4). For safety reasons,

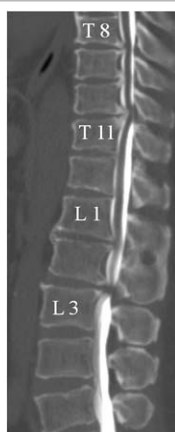


Figure 2: The CT myelography shows areas of OPLL extending from T8 to T11 and L1 to L3.

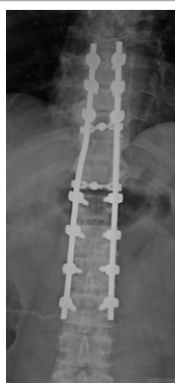


Figure 3: A postoperative radiographic image shows a posterior decompression with laminoplasty extending from T7 to L3.

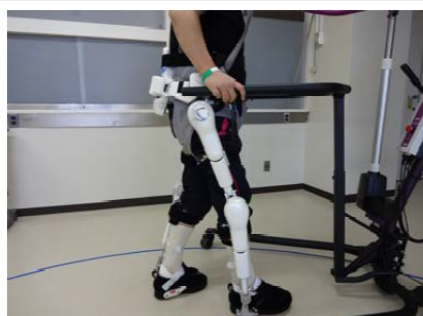

Figure 4: Gait training using the robot suit HAL® with a walking device and a harness for safety.

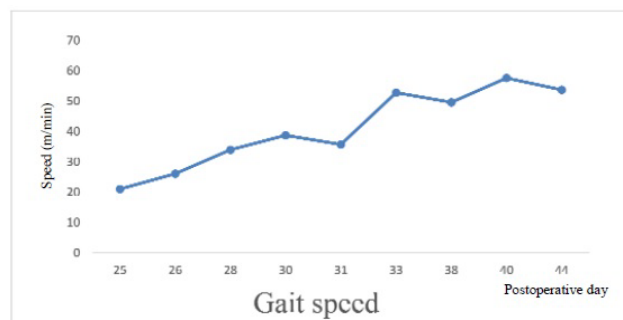


Figure 5: Change in 10MWT gait speed without HAL.

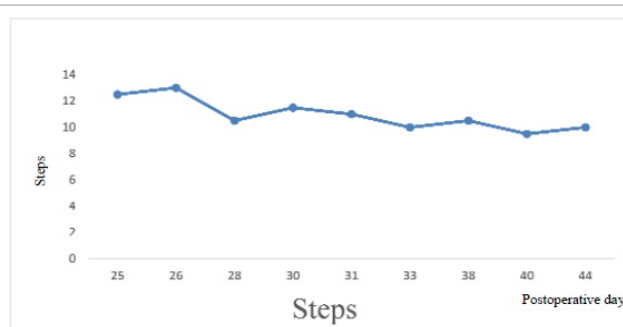


Figure 6: Change in 10MWT steps without HAL.

a walking device (AllinOne Walking Trainer) with a harness was used. The 60-minute training sessions consisted of single-leg motion, a standing and sitting exercise, and walking on the ground with HAL. Net gait training time was approximately 1520 minutes. Regarding such the HAL training program, we judged the fatigue and physical condition of the case, and we implemented HAL training. Motor weakness of both lower limbs improved to the MMT 4 level within one week. HAL training was finished on postoperative day 44 (7 weeks after surgery). The patient was able to walk 200300 m using crutches bilaterally under supervision by postoperative day 55. He was discharged from our hospital to his home on postoperative day 65 (9 weeks after surgery). Functional ambulation was assessed with the 10-m walk test (10 MWT) and the walking index for spinal cord injury (WISCI) II [9]. In the 10 MWT, the patient was instructed to walk without wearing HAL on a flat surface at a self-selected, comfortable pace. To calculate gait speed (m/s) as a primary outcome, the 10-m walking time was measured using a handheld stopwatch. In addition, the number of steps between the start and finish line was counted, and patient cadence was calculated from the walking time and number of steps. The extent of spinal cord injury was assessed with the ASIA (American Spinal Injury Association) impairment scale (AIS), ASIA score (lower limbs), and JOA (Japanese Orthopaedic Association) score. ADL (Activities of daily living) were assessed with the FIM (functional independence measure) motor score and Barthel index (BI).

Improvements in gait speed, steps, and cadence were observed gradually in the 10 MWT (Figures 5-7). Improvements in WISCI II was observed from level 13 (walker gait) to level 16 (two crutches) before and after the HAL training. The patient improved from 3 to 4-5 on the MMT in both lower limbs. Although we observed no change in AIS as D, improvements in the ASIA score (lower limbs) was observed from 26 to 50. Improvement in the JOA score, FIM motor score, and BI were observed from 1.5 to 5.5, from 44 to 81, and from 60 to 85, respectively (Table 1). No serious adverse events were observed during the rehabilitation training.

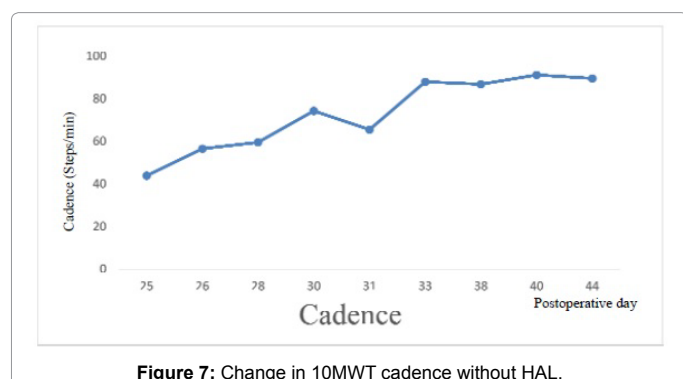


Figure 7: Change in 10MWT cadence without HAL.

	Baseline (POD13)	after the HAL training (POD47)
WISCI II	13	16
MMT (Lower limbs)	3	4-5
AIS Scale	D	D
ASIA score (lower limbs)	26	50
JOA Score	1.5	5.5
FIM motor score	44	81
BI	60	85

WISCI: Walking Index for Spinal Cord Injury; MMT: Manual Muscle Testing; AIS: American Spinal Injury, Association Impairment Scale; ASIA: American Spinal Injury Association; JOA: Japanese Orthopaedic Association; FIM: Functional Independence Measure; BI: Barthel Index; POD: Postoperative Day.

Table 1: Clinical assessment at baseline and after HAL training.

Discussion

Walking ability and muscle weakness of both legs were significantly improved after surgical treatment combined with HAL training in this case. Sakakima et al. reported that the walking ability of a thoracic OPLL patient with an inability to walk despite multiple surgeries was significantly improved using HAL training [10]. However, it takes a long time for paralysis to resolve before the patient can return home. HAL training has been applied to chronic spinal cord injuries, but there have been no previous reports on the effect of rehabilitation using HAL for severe thoracic spinal cord injuries (myelopathy) due to OPLL in the early phases of rehabilitation after surgical intervention.

Wu et al., reported that robotic resistance/assistance training using the original custom-designed cable-driven robotic gait training system improved gait speed, step length, and walking distance for the six minute walk test in 28 stroke patients with hemiplegia. Assistive training using the cable-driven robot during treadmill exercise might improve the motor learning mechanism. In addition, it was suggested that repetitive stepping assisted by the cable-driven robot might enhance the synaptic efficacy of sensorimotor pathways [11]. We have the impression that larger step length was observed during HAL training than conventional gait training in this case. Therefore, we think that HAL training affected the recovery of the motor function due to the motor learning. We also conjectured that the mechanism of this recovery of functional ambulation, sensory function, and coordination was due to changes in plasticity in the spinal cord and supraspinal centres by the HAL-induced motion, which has favourable feedback effects.

This is the first report that HAL training in the early postoperative phase has potential to improve a patient's mobility in severe thoracic spinal cord injury (myelopathy) due to OPLL with a prior inability to walk. The functional improvement in this case involved other treatment including both surgical treatment and conventional gait training. More patients will be needed to evaluate the isolated effects of HAL training.

This study was conducted with approval of the Ethics Committee of the Tsukuba University Faculty of Medicine.

Conflict of Interest

A commercial party having a direct financial interest in the results of the research supporting this article has conferred or will confer a financial benefit on 1 or more of the authors. Yoshiyuki Sankai is CEO of Cyberdyne Inc, Ibaraki, Japan. Hiroaki Kawamoto is a stockholder of the company. Cyberdyne is the manufacturer of the robot suit HAL. This study was proposed by the authors. Cyberdyne was not directly involved in the study design; collection, analysis, or interpretation of data; writing the report; or the decision to submit the paper for publication. No commercial party having a direct financial interest in the results of the research supporting this article has or will confer a benefit on the authors or on any organization with which the authors are associated (Shigeki Kubota, Tetsuya Abe, Kengo Fujii, Aiki Marushima, Tomoyuki Ueno, Ayumu Haginoya, Ayumu Endo, Hideki Kadone, Yukiyo Shimizu, Yasushi Hada, Akira Matsumura and Masashi Yamazaki).

Acknowledgement

We thank Mayuko Sakamaki and Yumiko Ito, Center for Innovative Medicine and Engineering (CIME), University of Tsukuba Hospital, for her excellent technical assistance. This study was supported by the Industrial Disease Clinical Research Grants of the Ministry of Health Labour and Welfare, Japan (14060101-01).

References

- Iwamoto Y (2013) Jinnaka's text book of orthopaedic surgery. In: Kozo Nakamura (ed.) Ossification of the posterior longitudinal ligament (OPLL), (23rd edn), Nanzando, Tokyo. p: 291-303.
- Kawamoto H, Sankai Y (2005) Power assist method based on phase sequence and muscle force condition for HAL. Adv Robot 19: 717-734.
- Colombo G, Joerg M, Schreier R, Dietz V (2000) Treadmill training of paraplegic patients using a robotic orthosis. J Rehabil Res Dev 37: 693-700.
- Colombo G, Wirz M, Dietz V (2001) Driven gait orthosis for improvement of locomotor training in paraplegic patients. Spinal Cord 39: 252-255.
- Hesse S, Uhlenbrock D, Werner C, Bardeleben A (2000) A mechanized gait trainer for restoring gait in nonambulatory subjects. Arch Phys Med Rehabil 81: 1158-1161.
- Hesse S, Werner C, Bardeleben A (2004) Electromechanical gait training with functional electrical stimulation: case studies in spinal cord injury. Spinal Cord 42: 346-352.
- Kubota S, Nakata Y, Eguchi K, Kawamoto H, Kamibayashi K, et al. (2013) Feasibility of rehabilitation training with a newly developed wearable robot for patients with limited mobility. Arch Phys Med Rehabil 94: 1080-1087.
- Aach M, Cruciger O, Sczesny-Kaiser M, Hoffken O, Meindl RCH, et al. (2014) Voluntary driven exoskeleton as a new tool for rehabilitation in chronic spinal cord injury: a pilot study. Spine J 14: 2847-2853.
- Dittuno PL, Dittuno JF Jr (2001) Walking index for spinal cord injury (WISCI II): scale revision. Spinal Cord 39: 654-656.
- Sakakima H, Ijiri K, Matsuda F, Tominaga H, Biwa T, et al. (2013) A newly developed robot suit hybrid assistive limb facilitated walking rehabilitation after spinal surgery for thoracic ossification of the posterior longitudinal ligament: a case report. Case Rep Orthop 621405.
- Wu M, Landry JM, Kim J, Schmit BD, Yen SC, et al. (2014) Robotic resistance/assistance training improves locomotor function in individuals poststroke: a randomized controlled study. Arch Phys Med Rehabil 95: 799-806.

Citation: Kubota S, Abe T, Fujii K, Marushima A, Ueno T, et al. (2016) Improvement of Walking Ability Using Hybrid Assistive Limb Training in a Patient with Severe Thoracic Myelopathy caused by Ossification of the Posterior Longitudinal Ligament - A Case Report. J Spine S7: 003.doi:[10.4172/2165-7939.S7-003](https://doi.org/10.4172/2165-7939.S7-003)

This article was originally published in a special issue, **Spinal Cord Injury Rehabilitation** handled by Editor(s). Dr. Alessandro Landi, University of Rome, Italy